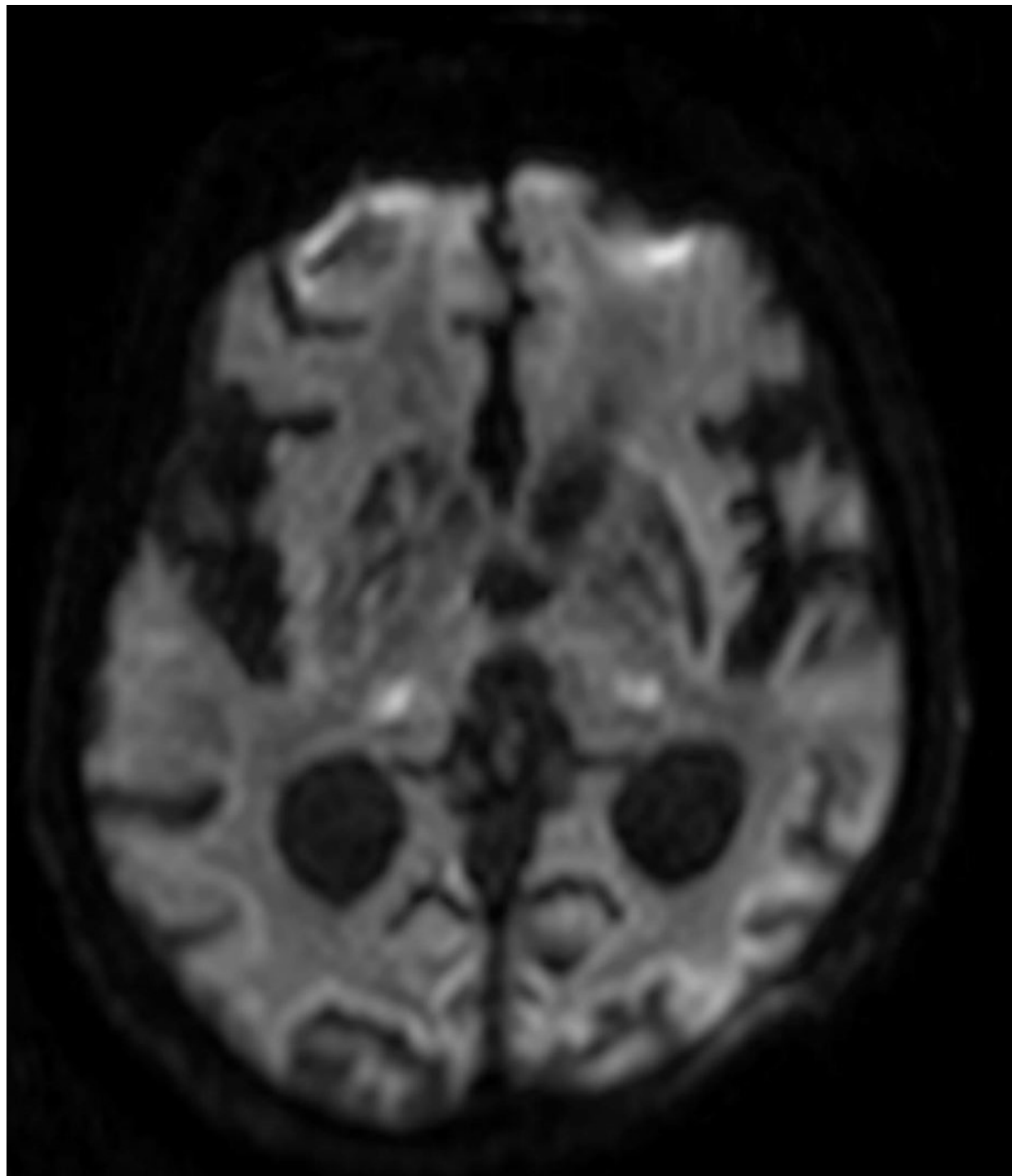
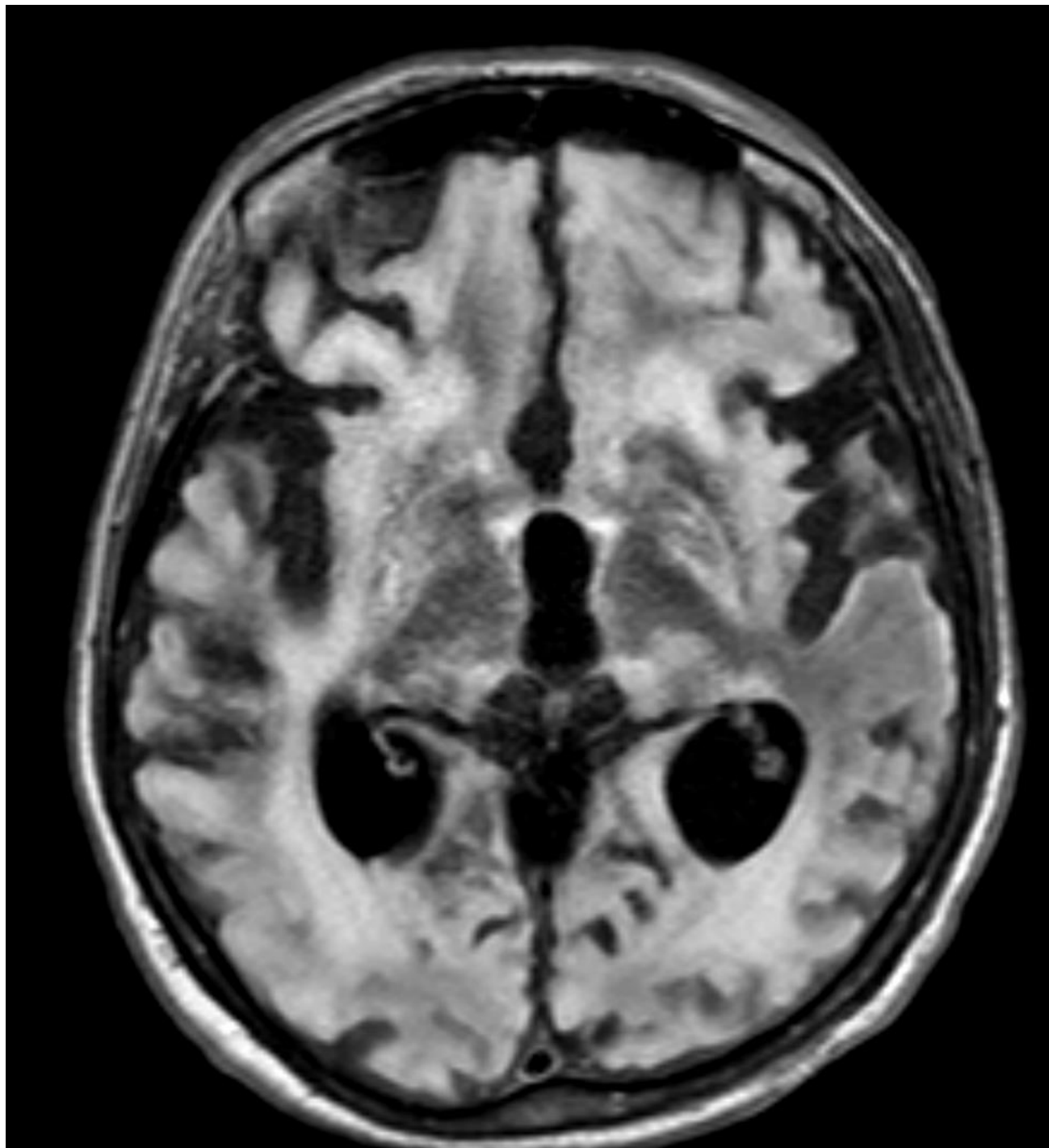


Prova Pratica #1

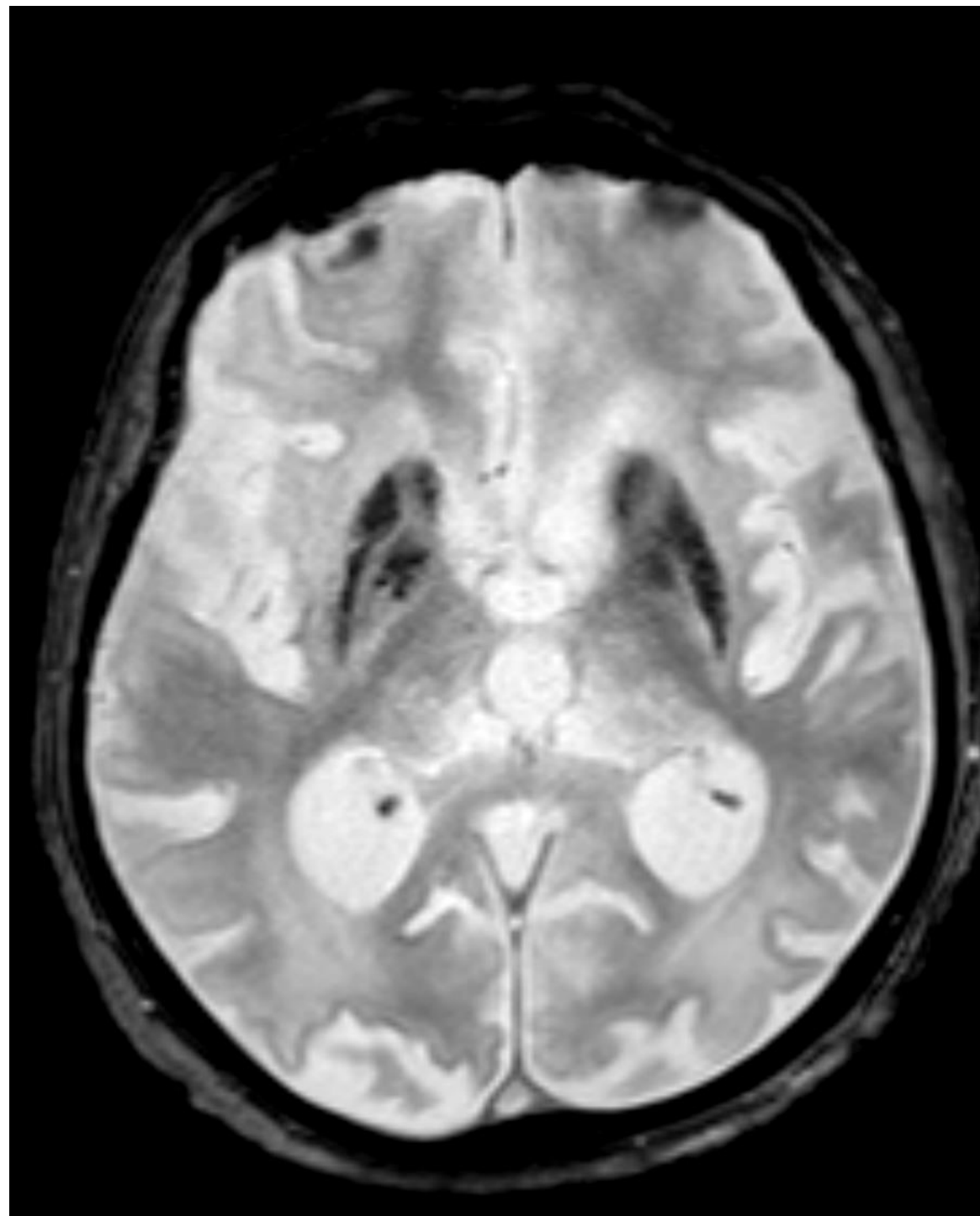
Donna di 73 anni, ricoverata in ospedale 2 mesi prima in stato di coma



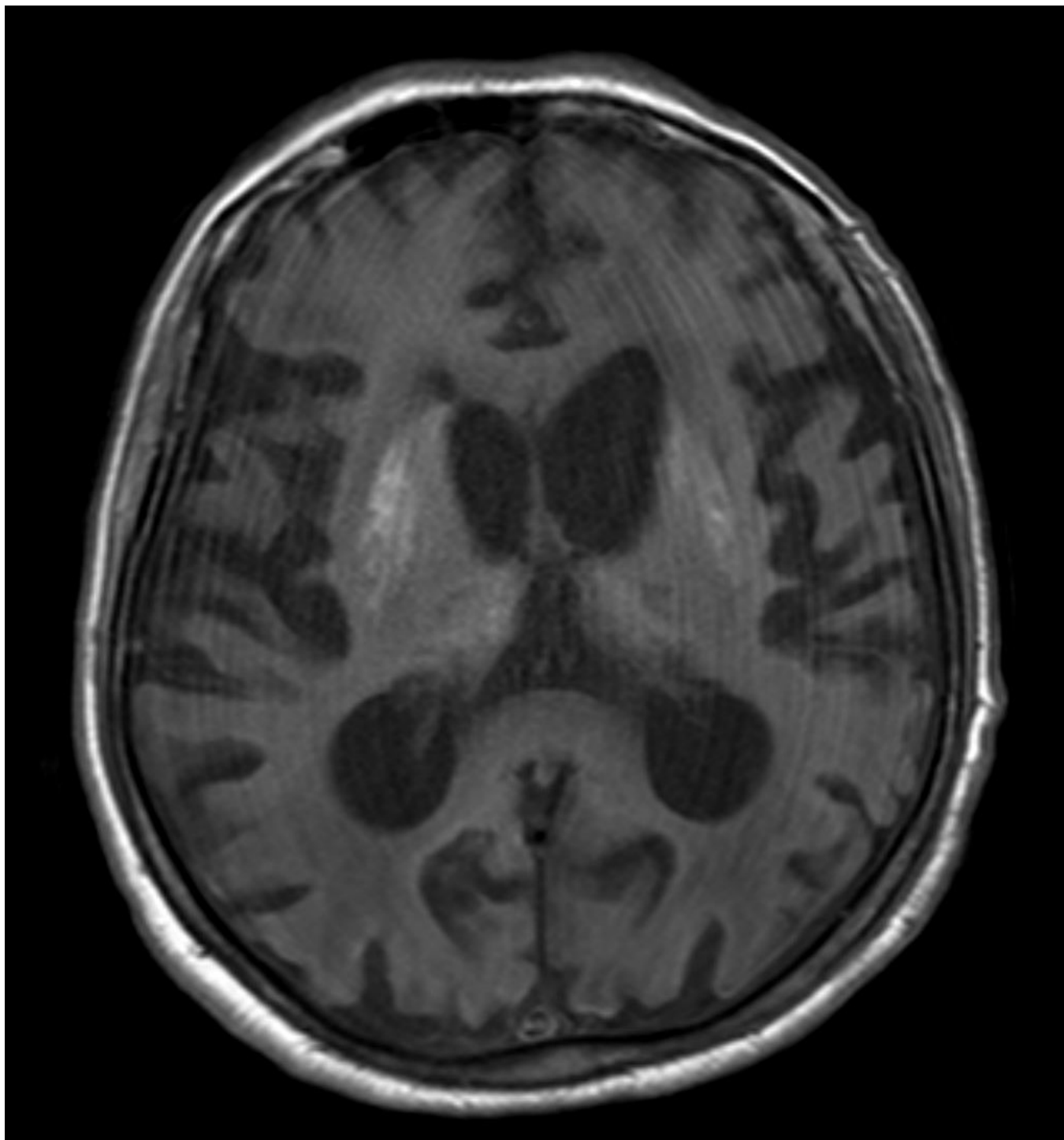
Prova Pratica #1



Prova Pratica #1

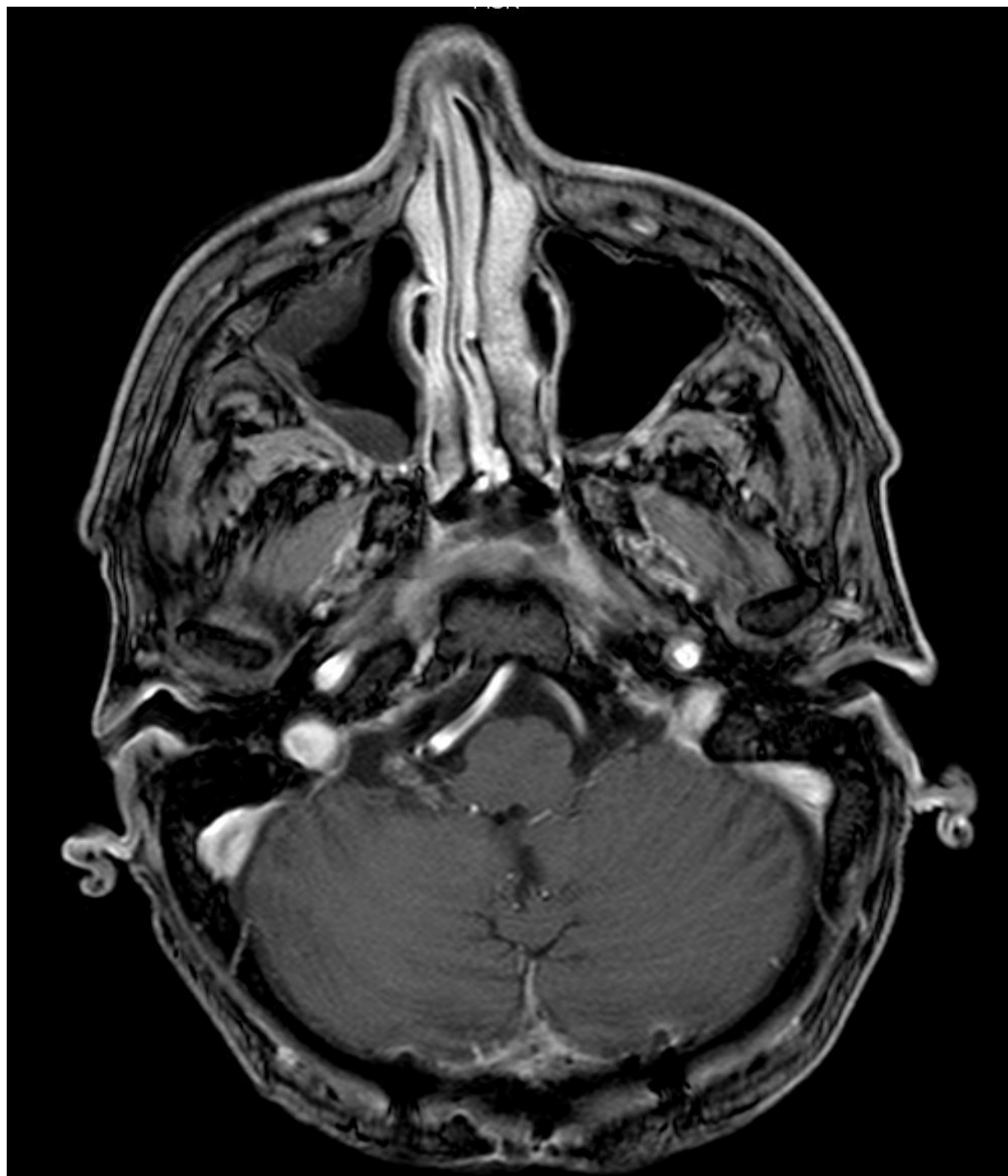


Prova Pratica #1

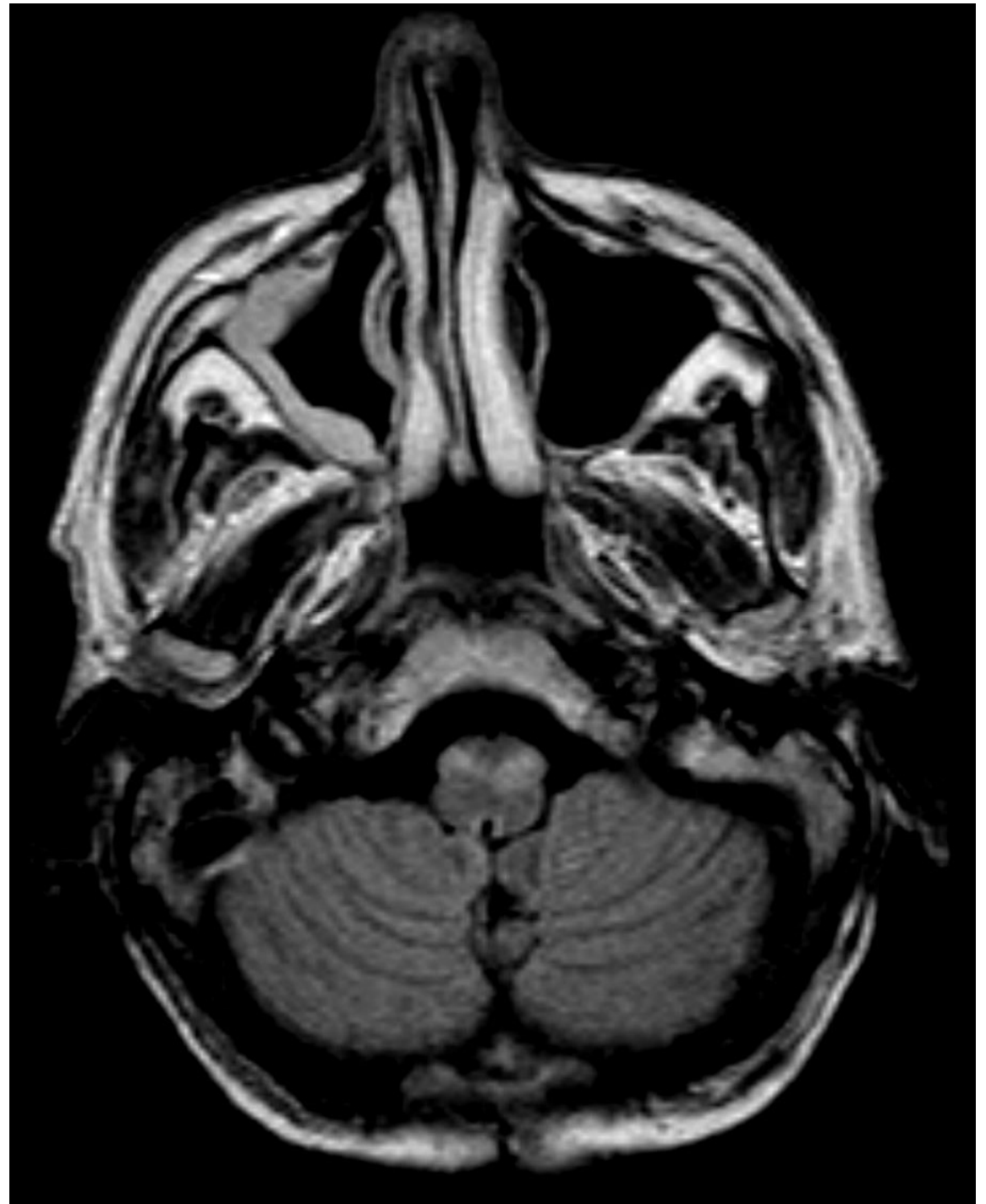


Prova Pratica #2

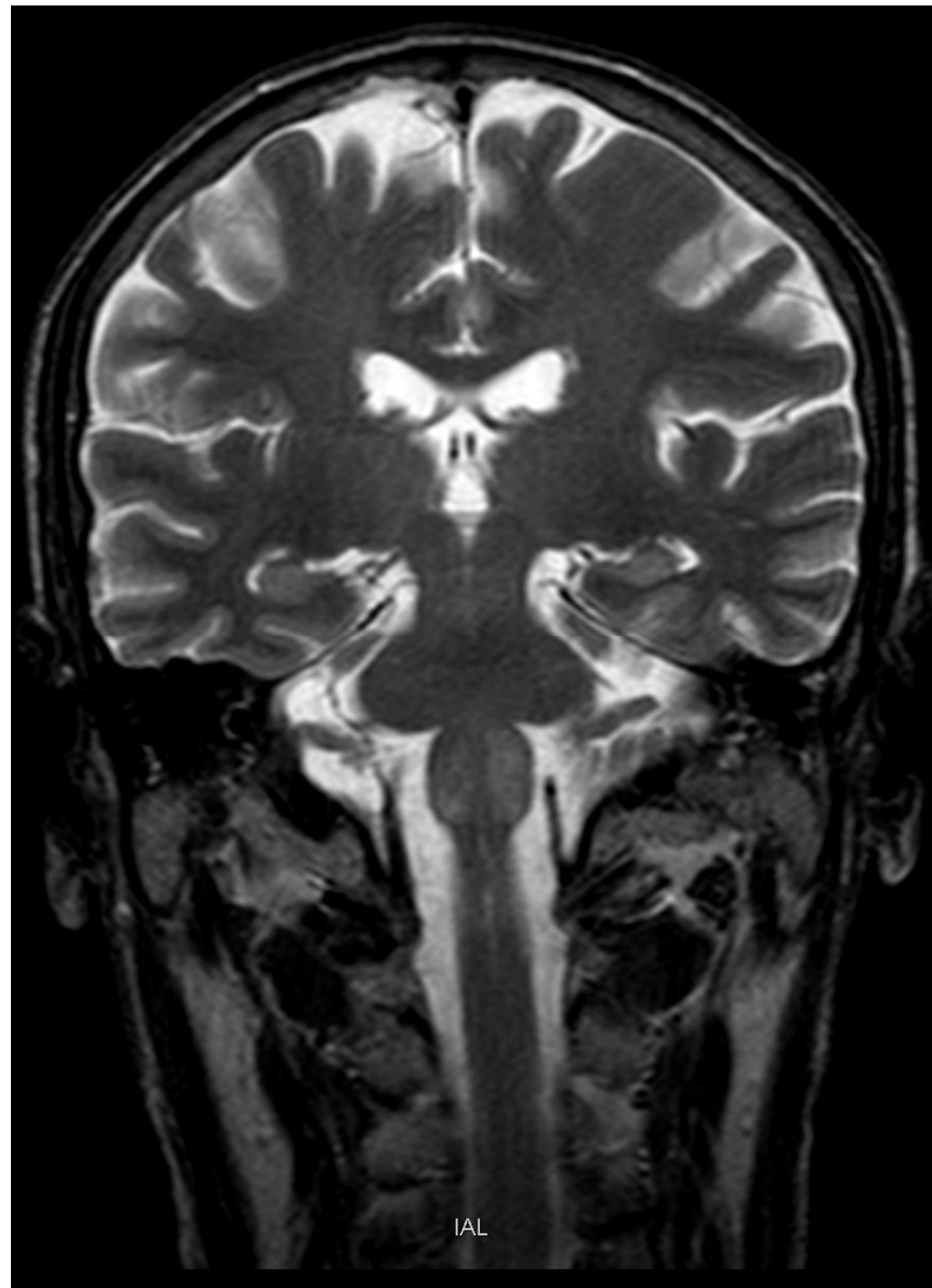
Uomo di 57 anni
con pregressa
diagnosi di
linfoma cerebrale
diffuso a grandi
cellule B



Prova Pratica #2

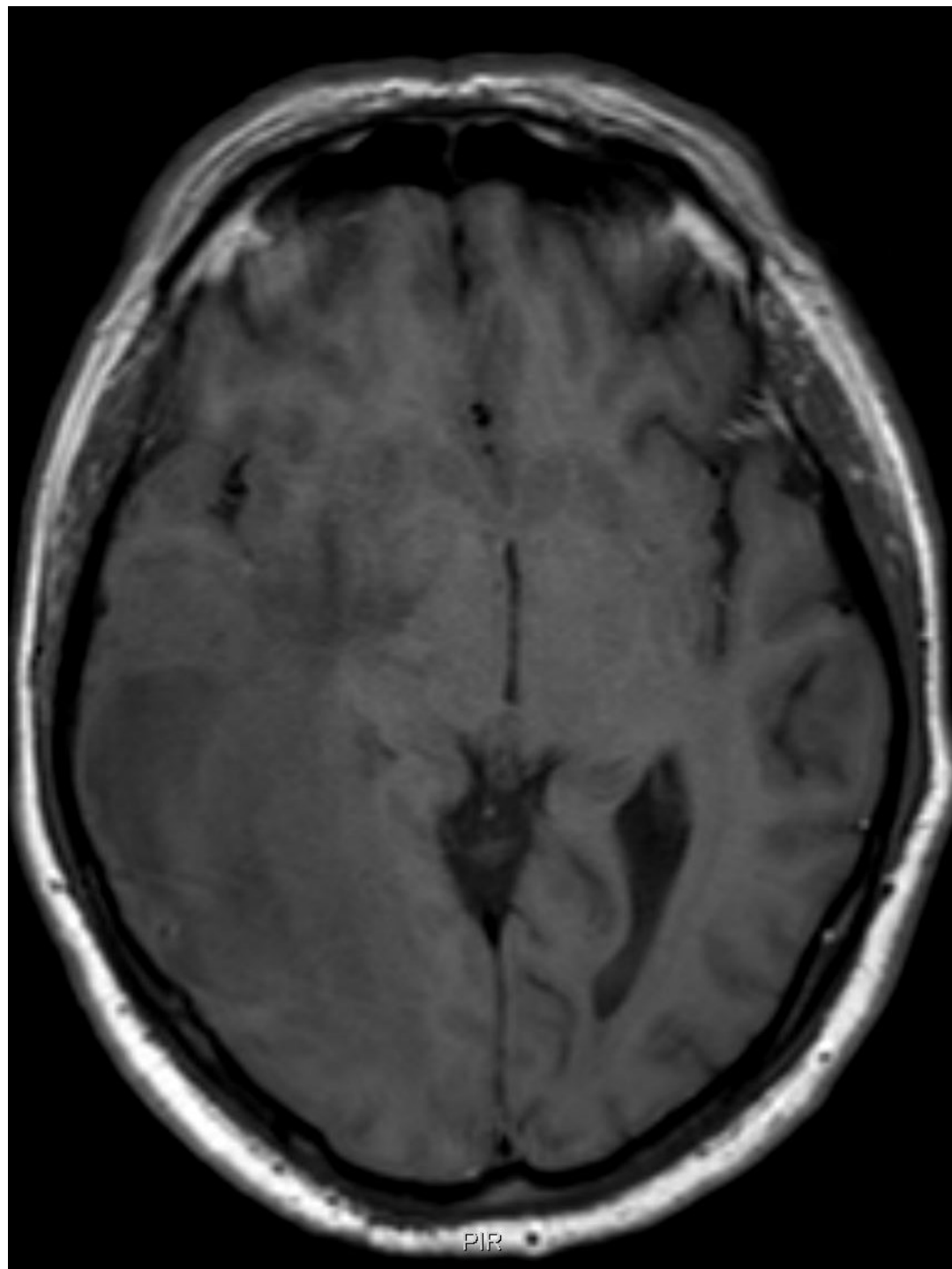


Prova Pratica #2

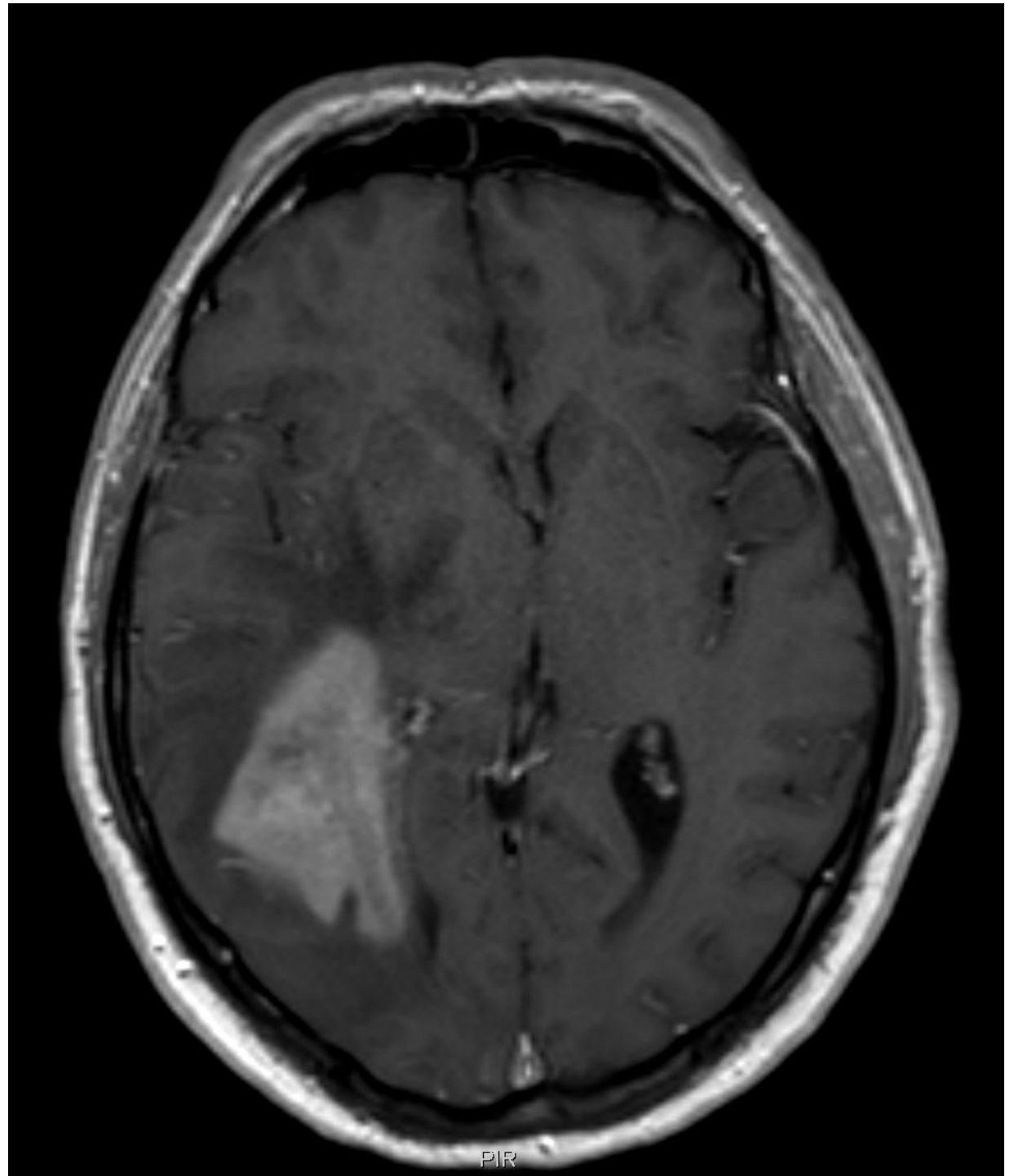


Prova Pratica #3

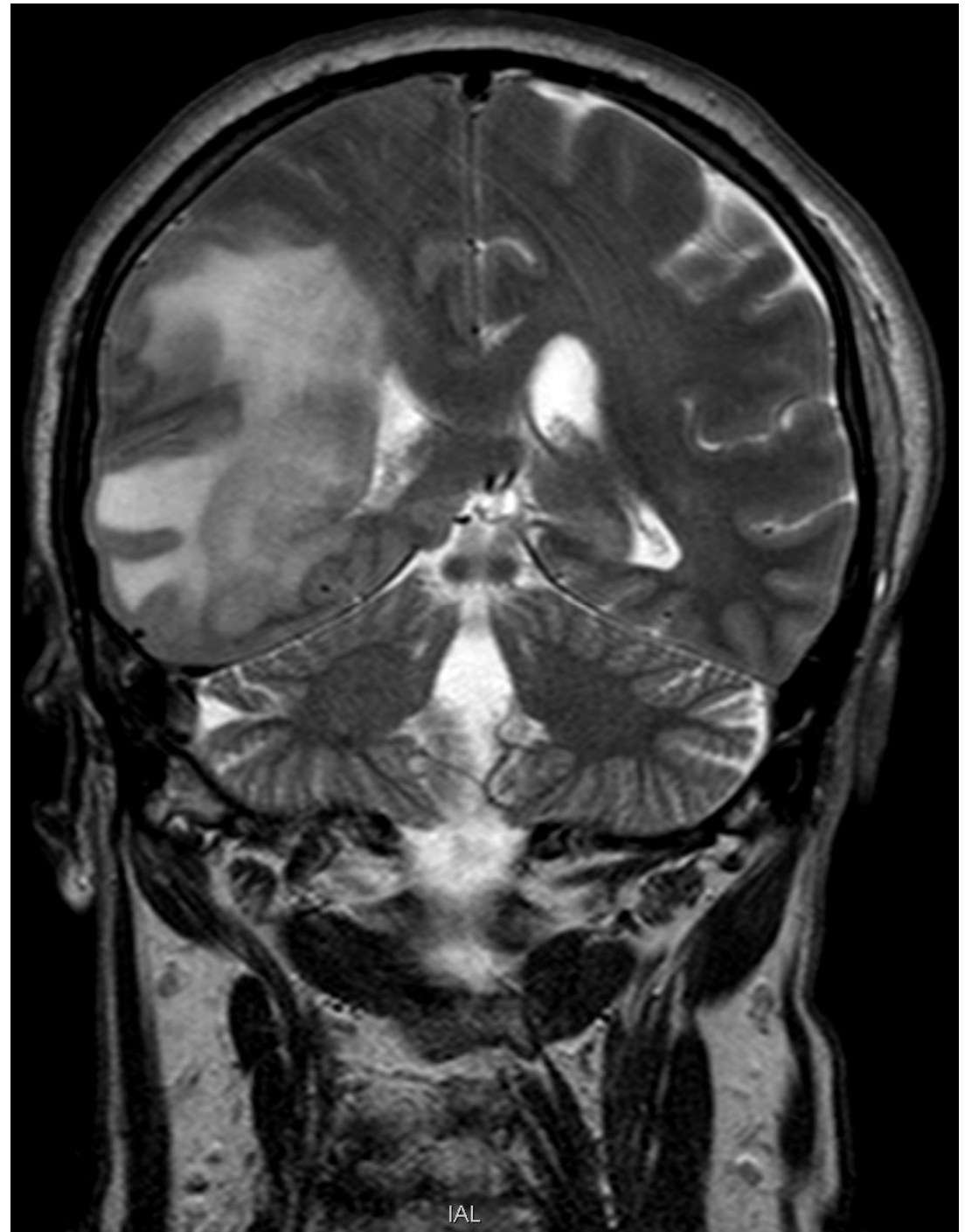
Uomo di 63 anni
con stato
confusionale e
problemi
comportamentali



Prova Pratica #3

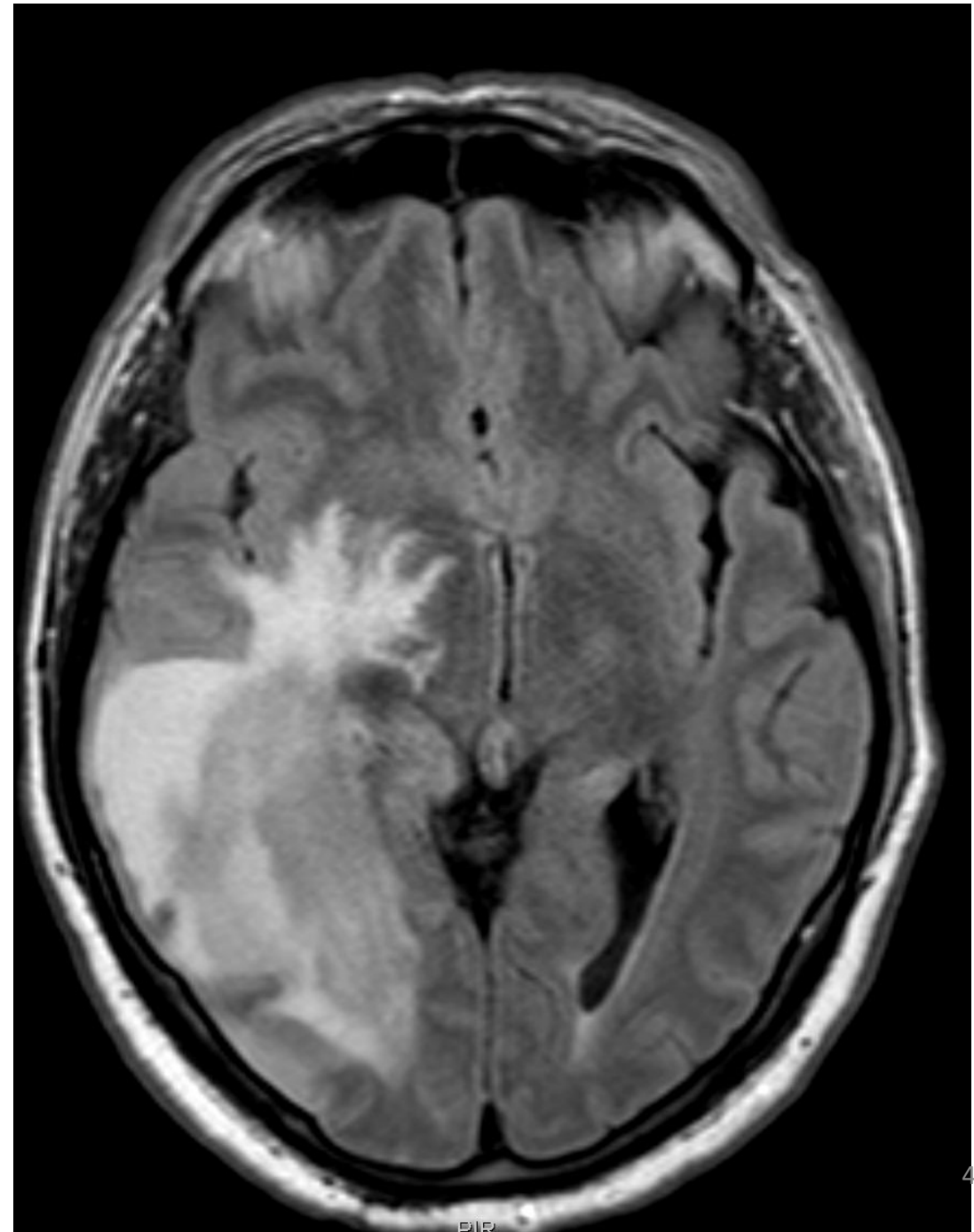


Prova Pratica #3

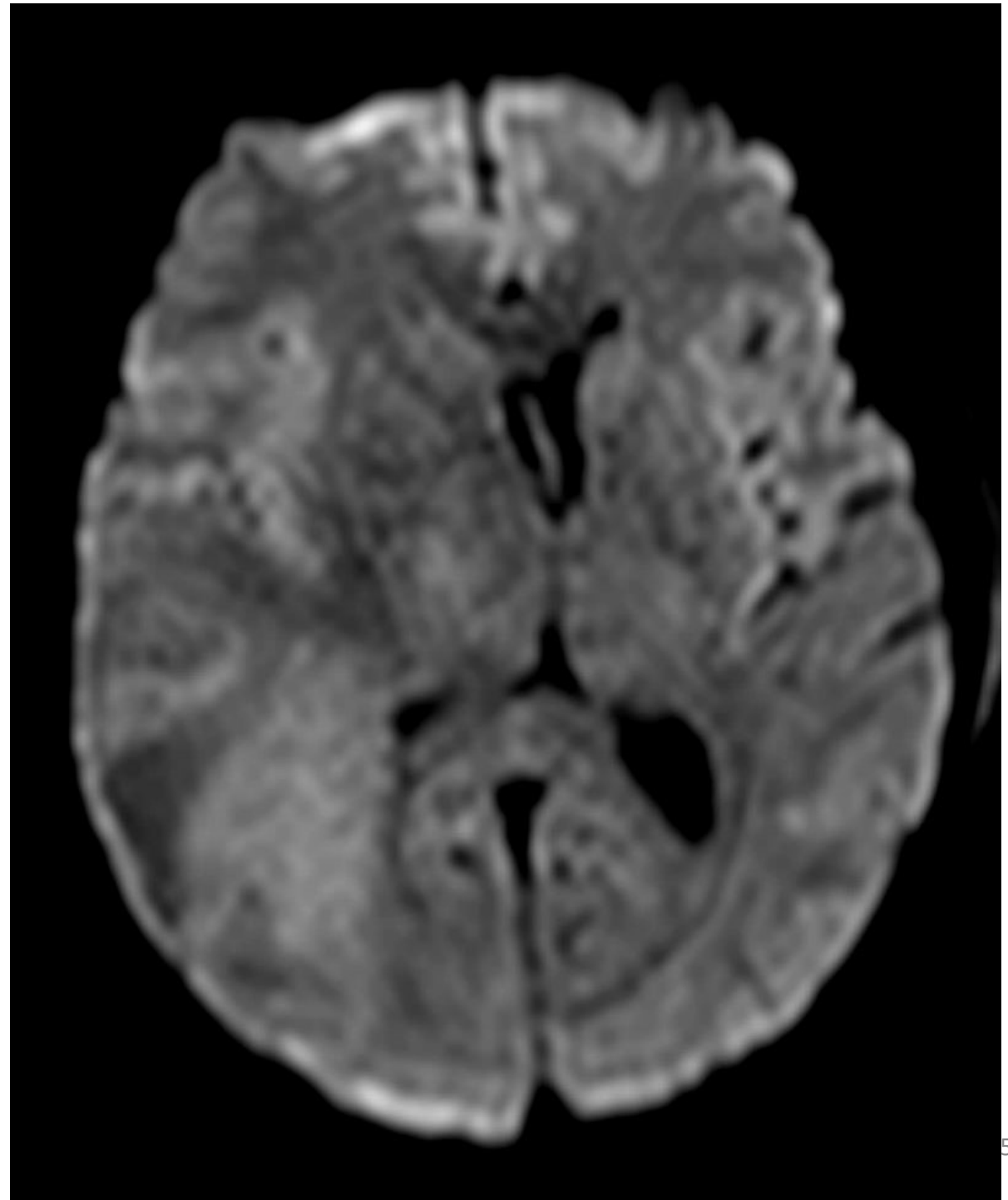


IAL

Prova Pratica #3



Prova Pratica #3



Prova Pratica #3

